



# Symptomatic Primary Hyperparathyroidism : A Retrospective Analysis of Fifty One Cases from a Single Centre

J Muthukrishnan\*, Sangeeta Jha\*, KD Modi\*, R Jha\*\*, J Kumar\*\*, A Verma\*, KVS Harikumar\*, Kiran Patro\*\*, B Srinivas\*\*, K Kumaresan\*\*\*, Rayudu Ramasubba+

## Abstract

**Objective:** Widely prevalent vitamin D deficiency and delayed diagnosis contributes to severe symptomatic primary hyperparathyroidism in India. We analysed fifty one consecutive patients of primary hyperparathyroidism managed at our centre. All of them were symptomatic.

**Design:** Retrospective analysis

**Material and Methods:** Fifty one consecutive cases of symptomatic primary hyperparathyroidism, presenting to our centre from January 1994 to May 2007 were retrospectively analyzed. Clinical presentation, biochemical, radiological and details of underlying parathyroid lesion were noted.

**Results:** A total of 51 cases of primary hyperparathyroidism were studied. Mean age was  $39.5 \pm 11.5$  yrs (Range 13 to 70 years, Female: Male 2:1). Mean duration of symptoms was  $35.8 \pm 29.1$  months. Bone pains and painful proximal myopathy were the commonest presentation (24/51), followed by pathological fractures in 12 cases. Distal Renal tubular acidosis was diagnosed in 4 cases, 3 of whom normalized after surgery. At initial evaluation, twenty one patients had elevated alkaline phosphatase with normal calcium levels indirectly suggesting associated vitamin D deficiency. Low serum levels of 25-hydroxy vitamin D were documented in five of them. Parathyroid carcinoma was diagnosed in 3 patients. Ectopic parathyroid adenoma was seen in 7 cases (3 mediastinal, 3 intrathyroidal, 1 near left carotid sheath). All the cases responded well to surgical excision.

**Conclusion:** Lack of universal screening for hypercalcemia, normocalcemia contributed by associated vitamin D deficiency and lack of awareness about unusual presentations of primary hyperparathyroidism led to delayed diagnosis in our patients. Delayed diagnosis and associated vitamin D deficiency in our patients contributed to greater severity of symptomatic primary hyperparathyroidism. ©

## INTRODUCTION

The disease spectrum in primary hyperparathyroidism varies from asymptomatic hypercalcemia to severe metabolic bone disease, pathological fractures and renal stones. Earlier studies from India have attributed the greater severity of primary hyperparathyroidism to delayed diagnosis and widely prevalent Vitamin D deficiency.<sup>1-4</sup> With this analysis from a tertiary care teaching hospital in south India, we aim to contribute to better characterization of primary hyperparathyroidism in our settings and support the earlier view regarding greater prevalence of symptomatic disease. In addition, we also highlight some

unusual presentations as a cause of delayed diagnosis of the disease.

## MATERIAL AND METHODS

Fifty one consecutive cases of primary hyperparathyroidism presenting to our centre from January 1994 to May 2007 were retrospectively analysed. Corrected serum calcium, inorganic phosphorus, alkaline phosphatase (ALP), serum creatinine and intact PTH levels were available for all patients. Limited skeletal survey and radionuclide parathyroid scan (Thallium-Techetium (Tc) subtraction scan, 99mTc Sestamibi or Tetrofosmin scan) were done to support the diagnosis and localize the culprit parathyroid lesion in all the cases. Diagnosis of primary hyperparathyroidism was established by presence of raised serum intact PTH with simultaneous raised corrected serum calcium. In cases with normocalcemia where there was a strong clinical and

Departments of \*Endocrinology, \*\*Nephrology, \*\*\*Nuclear Imaging and +Radiology, Medwin Hospital, Hyderabad, India.  
Received : 16.7.2007; Revised : 17.11.2007;  
Accepted : 30.4.2008

radiological suspicion of primary hyperparathyroidism, vitamin D supplementation with 1, 25 (OH)<sub>2</sub> vitamin D for two weeks was given. Serum calcium was repeated thereafter to look for hypercalcemia. In cases with persistent normocalcemia, cause for secondary hyperparathyroidism was ruled out by relevant investigations. Parathyroid adenoma with focal increased uptake on scintigraphy was taken as evidence of primary hyperparathyroidism. Work up for distal renal tubular acidosis (RTA) was done in patients with renal stones, hypokalemia or fasting urine pH>5.5. Plasma and Urine pH, bicarbonate levels and anion gap were tested in these patients. Distal RTA was diagnosed based on spontaneous or induced metabolic acidosis (Ammonium chloride loading test) with simultaneous urine pH>5.5.

All patients underwent surgical resection of the culprit parathyroid gland lesion. Radical neck dissection was done in two out of three cases of parathyroid carcinoma in whom the diagnosis of parathyroid carcinoma was suspected on clinical grounds and later confirmed on histopathology. The third case was diagnosed only on histopathology post-operatively. In the four cases of parathyroid hyperplasia, subtotal parathyroidectomy (3½ gland resection) was done. Per-operative findings regarding parathyroid gland location and histopathology of resected glands were noted. Details regarding post-operative follow up with clinical evaluation including tests for incipient hypoparathyroidism (Trousseau's and Chvostek's signs), serum calcium, inorganic phosphorus and alkaline phosphatase were noted. Normal Serum calcium and iPTH at follow up after one month of surgery was taken as criteria of cure of primary hyperparathyroidism.

## RESULTS

Fiftyone consecutive cases of primary hyperparathyroidism were studied. Their age varied from 13 years to 70 years (Mean 39.5 ± 11.5 yrs). The gender distribution was 34 females and 17 males. Mean Duration of Symptoms was 35.8 months (SD ± 29.1 months). Bone pains and muscle weakness was the predominant presentation seen in 24 (47%) of the cases. Pathological fractures in 12, recurrent renal stones in 7, and acute pancreatitis in 4 cases were the other modes of presentation. Three cases presented only with a solitary bone swelling, which was later diagnosed to be a brown tumor. Skeletal survey revealed diffuse osteopenia in 27 (53%) and classical changes of osteitis fibrosa cystica in 19 (37%) cases. Serum 25-hydroxy vitamin D levels were available in 5 patients with severe proximal myopathy and bone pains. It was low in all of them (Mean 4.8ng/dl, range 1.5 to 9.8 ng/dl). PTH levels were elevated in all the patients and ranged from 427 to 1152 pg/ml (Normal 10 - 65 pg/ml). Parathyroid scintigraphy was performed in all the cases. Relevant biochemical data and details of localization studies are tabulated in Table 1 and 2.

All patients underwent surgical management with resection of the culprit gland. All the cases responded well to surgical excision of the parathyroid lesion with normalization of calcium and iPTH levels. Forty patients were available for

follow up for a mean duration of 37 months (range - 3mths to 9 yrs). Biochemical assessment on follow up revealed normal calcium, phosphorus, ALP and iPTH levels. Three of the four cases of distal RTA responded well to parathyroid adenoma resection and became eumetabolic after surgery. One case continued to have metabolic acidosis despite normalization of calcium and PTH levels and is requiring long term potassium citrate supplementation (Table 3).

## DISCUSSION

Our study highlights a series of cases of primary hyperparathyroidism which were diagnosed late despite severe clinical manifestations. Similar trend is seen in reports from other parts of our country.<sup>1,2</sup> Vitamin D deficiency, which is seen in about 70% of our population, is responsible for severe bone and muscle pain as a presenting symptom.<sup>3-5</sup> Delay in diagnosis despite severe symptoms can be attributed to lack of universal screening for hypercalcemia and normocalcemia related to vitamin D deficiency. Unusual presentations with renal tubular acidosis, acute/chronic pancreatitis and solitary lytic bone lesions also contributed to delayed diagnosis in our patients.

All the patients were symptomatic. Painful proximal myopathy and bone pains were seen in 47% of our cases. Forty seven patients (92%) had skeletal radiological changes of primary hyperparathyroidism. Three cases presented with solitary bone swellings and lytic bone lesion on X-ray posing a diagnostic challenge to the treating surgeon. Alert radiologist with an eye for subtle changes of primary hyperparathyroidism suggested the diagnosis in these cases. Nephrocalcinosis in 7 and renal stone disease in 6 patients were the common renal involvement noted. Distal RTA rarely occurs as a result of hypercalciuria related renal tubular dysfunction.<sup>6</sup> We encountered 4 cases of distal RTA in our series. Three of them responded with complete normalization of acid-base

Table 1 : Biochemical characteristics of patients with primary hyperparathyroidism

Biochemical Abnormality	No. of Cases (%)
Hypercalcemia	40 (78)
Normal Calcium	11 (21)
Raised PTH	51 (100)
Hypophosphatemia	48 (94)
Raised Alkaline Phosphatase	36 (70)
Distal Renal Tubular Acidosis	4 (8)

Table 2 : Radiological features and localisation techniques in primary hyperparathyroidism

Localisation Technique	Positive (Total done)
Tc99m Sestamibi Scan	38 (38)
Tc99m TetraFosmin scan	01 (01)
Thallium-Technetium Subtraction Scan	12 (12)
CT Scan	6 (6)*
Ultrasonography	7 (7)*

\* Confirmed by Sestamibi scan

Table 3 : Clinical and laboratory parameters of cases with distal renal tubular acidosis secondary to primary hyperparathyroidism

Characteristics	Case 1	Case 2	Case 3	Case 4
Age (yrs)/gender	22/F	16/F	42/F	56/M
Presentation	Proximal myopathy, bone pains	Bony deformity, pains	Loss of ht, kyphoscoliosis, bone pains	Recurrent renal stones
Ca/P (mg/dl)ALP (IU/l)	10.8/2.4480	11.2/2.61200	11/2.6399	11.5/2.8290
iPTH (pg/ml)	702.5	915	228	352
S. Creatinine (mg/dl)	0.5	0.4	0.8	1.8
Fasting Urine pH	6.0	7.0	7.5	7.4
ABG - pH, HCO <sub>3</sub> (mEq/l)	7.36, 17	7.35, 17	7.38, 10	7.3,16
Parathyroid scintigraphy	Lt superior adenoma	Lt inferior adenoma	Lt inferior adenoma	Lt inferior adenoma
Post op RTA status	Cured	Cured	Cured	Persistent

status after resolution of hyperparathyroidism while one had persistent metabolic acidosis during follow up despite complete cure of underlying primary hyperparathyroidism. All the four cases of distal RTA were noted to have solitary parathyroid adenoma with rest of the parathyroid glands being normal, thus excluding secondary or tertiary hyperparathyroidism. Reversal of distal RTA after correction of primary hyperparathyroidism further established primary hyperparathyroidism as the cause of distal RTA in three of these four cases. Delayed correction of the hyperparathyroid state in one case was the likely reason for persistent RTA after surgery. Hypercalcemia due to primary hyperparathyroidism can occasionally lead to involvement of the exocrine pancreas and present with acute, recurrent or chronic calcific pancreatitis.<sup>(7, 8)</sup> Presence of normal or increased serum calcium in the setting of acute pancreatitis raised the suspicion of primary hypercalcemic state as the underlying cause in four cases in our series (Fig. 1). A case of chronic calcific pancreatitis presented with recurrent pain abdomen and diarrhea with pancreatic calcifications noted on abdominal radiograph (Fig. 2).

The underlying pathology in 44 patients was solitary parathyroid adenoma. Parathyroid hyperplasia was the cause in 4 cases in whom there was no history of familial primary hyperparathyroidism. Three cases of parathyroid carcinoma noted by us are similar to earlier Indian studies and greater than the prevalence reported in western literature.<sup>1,9,10</sup> Role of Vitamin D deficiency in greater tumor mass has been noted in earlier studies but its role in greater incidence of parathyroid carcinoma needs further analysis.<sup>5</sup>

Diagnosis of primary hyperparathyroidism is suggested by hypercalcemia, hypophosphatemia and raised intact PTH in appropriate clinical settings. In presence of normal serum calcium with raised PTH levels, secondary hyperparathyroidism needs to be excluded by detailed clinical and biochemical evaluation. This biochemical picture may also be seen in primary hyperparathyroidism with vitamin D deficiency and low dietary calcium intake and as a manifestation of early stages of primary hyperparathyroidism.<sup>9</sup> In our series, 30 out of 51 cases had hypercalcemia at initial evaluation. Amongst 21 cases

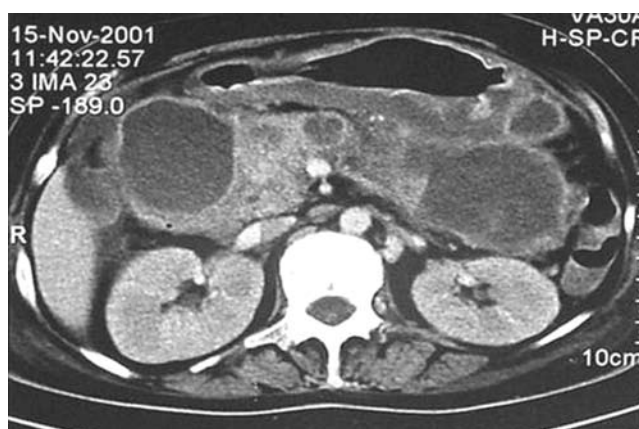


Fig. 1 : CT scan of abdomen in a case of primary hyperparathyroidism with acute pancreatitis.

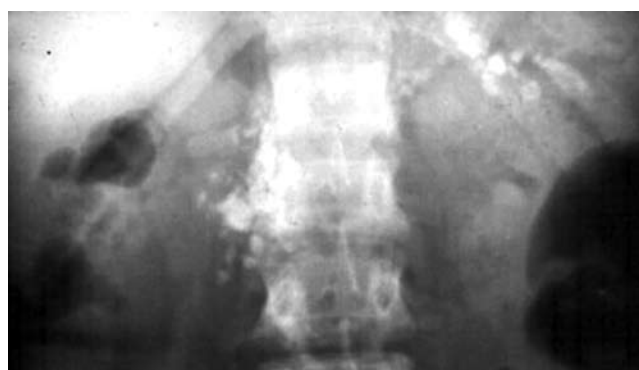

Fig. 2 : Plain radiograph of abdomen showing calcific opacities in the pancreas in a case of primary hyperparathyroidism with chronic calcific pancreatitis.

with normocalcemia, primary hyperparathyroidism was suspected on the basis of clinical and radiological features. Serum calcium increased to levels above upper limit of normal in 10 of these cases with vitamin D replacement over two weeks. In 5 out of these 10 cases, serum 25-hydroxy vitamin D levels were done and found to be low in all of them.

In the remaining 11 cases with persistent normocalcemia despite vitamin D supplementation, underlying cause for secondary hyperparathyroidism was ruled out by relevant investigations. Based on clinical profile and radiological features suggestive of primary hyperparathyroidism, they

were subjected to parathyroid scintigraphy. Presence of solitary parathyroid adenoma on scintigraphy was used to establish the diagnosis of primary hyperparathyroidism.

Pre-operative <sup>99m</sup>Tc Sestamibi scan helps in localizing the tumor accurately in almost 90% of patients.<sup>11</sup> All our patients underwent localizing studies with nuclear imaging. Six patients including three with parathyroid carcinoma underwent computed tomography of the neck for evaluation of tumor location and extension. Ultrasonography has shown satisfactory sensitivity in localizing parathyroid adenoma.<sup>12</sup> In this series, USG examination of the neck could correctly localize the adenoma in all the seven cases where it was used. Nuclear imaging for parathyroids has a greater role in localizing ectopic glands which helps the surgeon in planning the surgical approach. Seven patients in our series had ectopic parathyroid adenoma. Three were located within the thyroid gland, three in superior mediastinum and one located laterally near the left carotid sheath. All the patients underwent successful surgical resection of the culprit lesion. One patient with ectopic left inferior parathyroid gland adenoma located near the left carotid sheath, had a failed surgical exploration in the first attempt and the tumor was successfully removed on re-exploration after one month. Of the three cases of parathyroid carcinoma, diagnosis was suspected in two cases on clinical grounds due to aggressive disease course, palpable neck mass, severe hypercalcemia and markedly raised PTH. Both cases underwent radical neck dissection and diagnosis was confirmed post-operatively on histopathology. In the third case, there was no pre-operative clinical suspicion or intra-operative findings suggestive of parathyroid carcinoma. The diagnosis of parathyroid carcinoma was established only post-operatively on histopathological examination of the resected tumor. This patient was not available for subsequent follow up. In the four cases of parathyroid hyperplasia, there was no family history of hyperparathyroidism or other endocrine gland involvement suggestive of multiple endocrine neoplasia (MEN). Subtotal parathyroidectomy (3½ gland resection) was successfully done in all of them. None of our cases had recurrent laryngeal nerve injury or persistent hypoparathyroidism after surgery. Symptomatic hypocalcaemia due to avid calcium uptake by previously resorbed bones (Hungry Bone disease) usually occurs in cases that have more severe symptomatic bone disease.<sup>13</sup> Five patients who presented initially with severe myopathy and bone disease had hungry bone disease which required parenteral calcium replacement for up to two weeks after the surgery. Forty patients who were available for follow up for varying time periods showed complete resolution of bone pains, muscle aches and weakness. Follow up biochemical evaluation showed normalization of calcium and iPTH levels and radiological improvement in bone lesions.

Primary hyperparathyroidism in our country is known to present with severe metabolic bone disease due

to coexistent vitamin D deficiency. Delay in diagnosis despite severe symptoms is contributed to by unusual manifestations like distal RTA, pancreatitis and solitary bony swellings which often present as diagnostic dilemma as seen in our series. Though majority of our cases had solitary parathyroid adenoma, carcinoma of parathyroid gland was seen with greater frequency (7.8%). Nuclear imaging was the commonest localizing modality which proved helpful in cases with ectopic glands. Possibility of primary hyperparathyroidism should always be kept in mind while dealing with cases of lytic bone lesions. Replacement of calcium and vitamin D in patients with primary hyperparathyroidism deficient in vitamin D, may help in improving their symptoms and reducing the severity of post-operative hungry bone disease. Role of Vitamin D deficiency in contributing to greater prevalence of parathyroid carcinoma than that reported in western literature needs further evaluation.

#### Acknowledgement

The authors wish to gratefully acknowledge the assistance rendered by Ms Mrunalini Reddy in preparation of this manuscript.

#### REFERENCES

1. Bhansali A, Masoodi SR, Reddy KS, et al. Primary hyperparathyroidism in north India: a description of 52 cases. *Ann Saudi Med* 2005;25:29-35.
2. Mishra SK, Agarwal G, Kar DK, et al. Unique clinical characteristics of primary hyperparathyroidism in India. *Br J Surg* 2001;88:708-14.
3. Arya V, Bhambri R, Godbole MM, Mithal A. Vitamin D status and its relationship with bone mineral density in healthy Asian Indians. *Osteoporos Int* 2004;15:56-61.
4. Harinarayan CV, Gupta N, Kochupillai N. Vitamin D status in primary hyperparathyroidism in India. *Clin Endocrinol (Oxf)*. 1995;43:351-8.
5. Rao DS, Agrawal G, Talpos GB, et al. Role of vitamin D and calcium nutrition in disease expression and parathyroid tumor growth in primary hyperparathyroidism: A global perspective. *J Bone Miner Res* 2002;17:N75-N80.
6. Rodriguez SJ. Renal Tubular Acidosis: The Clinical Entity. *J Am Soc Nephrol* 2002;13:2160-70.
7. Sanjay K Bhadada, Harsh P Udawat, Anil Bhansali et al. Chronic pancreatitis in primary hyperparathyroidism: Comparison with alcoholic and idiopathic chronic pancreatitis. *J Gastroenterol Hepatol* 2007 (Online EarlyArticles). doi:10.1111/j.1440-1746.2007.05050.x
8. Jacob JJ, John M, Thomas N, et al. Does hyperparathyroidism cause pancreatitis? A South Indian experience and a review of published work. *ANZ J Surg* 2006;76:740-4.
9. Silverberg SJ, Bilezikian JP. "Incipient" Primary Hyperparathyroidism: a "forme fruste" of an old disease. *J Clin Endocrinol Metab* 2003;88:5348-52.
10. Agarwal G, Prasad KK, Kar DK, et al. Indian primary hyperparathyroidism patients with parathyroid carcinoma do not differ in clinico-investigative characteristics from those with benign parathyroid pathology. *World J Surg* 2006;30: 732-42.
11. Dillavou AD, Jenoff JS, Intenzo CM, Cohn HE. The utility of Sestamibi scanning in the operative management of patients with primary hyperparathyroidism. *J Am Coll Surg* 2000;190:540-5.
12. Bhansali A, Masoodi SR, Bhadada S, et al. Ultrasonography in detection of single and multiple abnormal parathyroid glands in primary hyperparathyroidism: comparison with radionuclide scintigraphy

and surgery. Clin Endocrinol (oxf) 2006;65:340-5.

13. Graal MB, Wolffenbuttel BHR. Consequences of long-term hyperparathyroidism. The Neth J Med 1998; 53(1): 37-42.

### Announcement

#### ICP - CME, KOTA - 2008

On Sunday, 9th November, 2008

Organised by : API, Kota Chapter

For further details please contact : Dr. SK Goyal, Organising Chairman, 2-Ka-21, Vigyan Nagar, Kota - 324005. Mob. : 92980-08158; Email : sukugoyal2001@yahoo.com

Dr. KK Pareek, Chairman, Scientific Committee, "Shri Krishna" 1-A-8, (SFS) Talwandi, Kota - 324006.  
Tel.: 0744-2426538 (R); 0744-2402271 (H)

Dr. Girish Mathur, Organising Secretary, 740-E, CAD Circle, Kota 324009.  
Tel.: 0744-2501224, 2502040; Mobile : 9414177040; Email : girishmathur2007@gmail.com