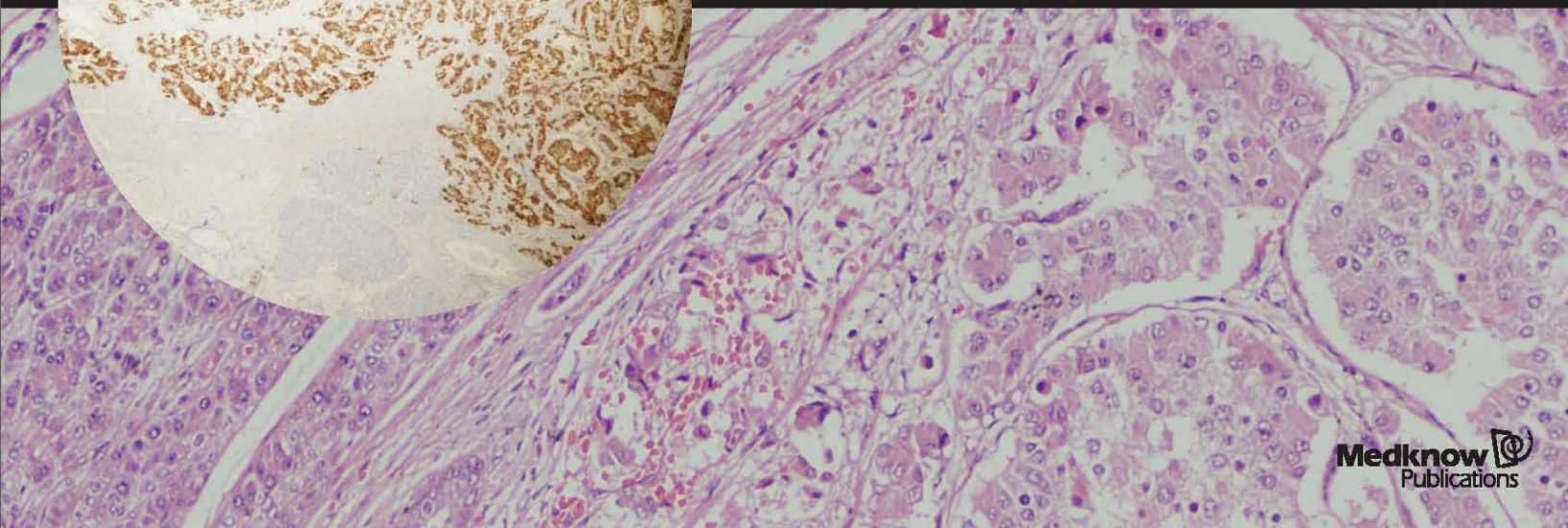
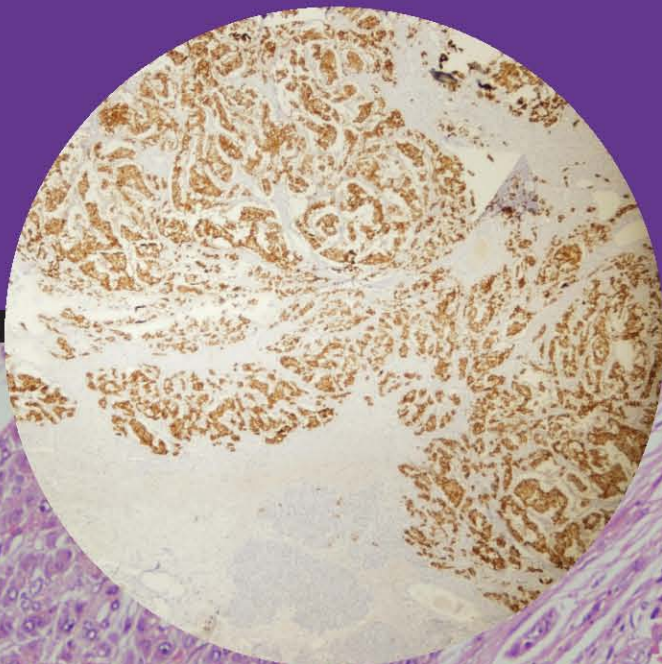


April 2011 / Vol 15 / Issue 2

Indian Journal of Endocrinology and Metabolism

Official Publication of The Endocrine Society of India

www.ijem.in



Case Report

17- α -Hydroxylase deficiency: An unusual case with primary amenorrhea and hypertension

Sunil Kumar Kota, Kirtikumar Modi, Ratan Jha¹, Surya Narayan Mandal¹

Departments of Endocrinology and ¹Nephrology, Medwin Hospital, Hyderabad, Andhra Pradesh, India

ABSTRACT

A 14-year-old girl presented with acute onset quadriparesis and newly detected hypertension. Parental consanguinity, delayed puberty with normal stature form the additional information. Hypokalemia with metabolic alkalosis, low cortisol, high ACTH and FSH pointed to the possibility of CAH with 17 α hydroxylase deficiency. 46XX karyotype and high progesterone supported this. Normalization of hypokalemia and hypertension with glucocorticoid treatment confirmed the diagnosis. In summary, the possibility of 17 OHD should be suspected in patients with hypokalemic myopathy, Hypertension and hypogonadism so that appropriate therapy can be implemented.

Key words: 17- α -hydroxylase deficiency, delayed puberty, hypertension, hypokalemia

INTRODUCTION

17- α -Hydroxylase deficiency (17OHD) is a rare form of congenital adrenal hyperplasia resulting from mutation in CYP17 gene.^[1] The gene is expressed in adrenal gland and gonads but not in placenta and ovarian granulosa cells.^[2] It is an autosomal recessive defect leading to deficiency in glucocorticoid, adrenal androgen, and sex steroid synthesis with concomitant mineralocorticoid excess. Patients present with hypertension and hypokalemia with undervirilized state in males and delayed puberty in females. It has an estimated incidence of approximately 1 in 50,000 individuals.^[3] To date approximately 150 cases of 17- α -hydroxylase deficiency have been reported.^[4] Here we report one female case with clinical, hormonal, and metabolic characteristics typical of 17OHD.

CASE REPORT

A 14-year-old girl presented with acute onset quadriparesis and hypertension. Parental consanguinity, primary amenorrhea, and absent breast development form the additional information. On examination, BP was 150/100 mmHg without significant asymmetry or postural variation with palpable pulses in all extremities. Her height was 157 cm and weight was 45 kg. There was generalized skin fold and knuckle pigmentation without mucosal pigmentation. Sexual maturity rating was B1 PH1.^[5] Axillary hairs were absent. Muscle power was grade 3 with normal deep tendon reflexes and intact sensory, bladder, and bowel functions. Rest of the systemic examination was normal. Investigations revealed hypokalemia (serum potassium, 1.9 meq/L), low 24 h urine potassium (7 meq/day) with metabolic alkalosis (pH, 7.6, HCO₃, 30 mmol/L, PaCO₂ 40 mmHg). Other positive investigations were low serum cortisol (1.5 mcg/dL), high ACTH (513 pg/mL), and high FSH (45 mIU/L). Her karyotype was 46XX and serum progesterone was elevated (8.5 ng/mL, normal < 1.5 ng/mL).

Combination of hypergonadotropic hypogonadism (primary amenorrhea, breast B1 stage with high FSH) adrenal insufficiency (low cortisol with high ACTH)

Access this article online

Quick Response Code:



Website:
www.ijem.in

DOI:
10.4103/2230-8210.81945

Corresponding Author: Dr. Sunil Kumar Kota, Department of Endocrinology, Medwin Hospitals, Chiragh Ali Lane, Nampally, Hyderabad - 500 001, Andhra Pradesh, India. E-mail: hidocsunil@ibibo.com

and hypertension with metabolic alkalosis (signifying mineralocorticoid excess) in a girl of pubertal age led to the provisional diagnosis of 17OHD. Serum progesterone being the immediate proximal hormone, prior to 17- α -hydroxylase was elevated confirming the diagnosis of 17OHD. She was prescribed potassium supplementation, prednisolone 10 mg at bedtime, ethinyl estradiol 10 μ g, and amlodepin 5 mg daily. Quadriparesis resolved over 1 day. After 2 weeks amlodepin and potassium supplements could be withdrawn without recurrence of hypokalemia and hypertension. Two months later, after stopping prednisolone for 4 days, her tests showed: plasma renin activity < 0.1 ng/mL/h and aldosterone 428.8 pg/mL (normal: 40-480 pg/mL). Prednisolone 10 mg and ethinyl estradiol 10 μ g/day were continued. After 3 months due to cushingoid facial features, bedtime prednisolone was replaced with 0.5 mg of dexamethasone.

DISCUSSION

The classical presentation of 17OHD is hypertension, hypokalemia, and delayed puberty with lack of secondary sexual characteristics in a female of pubertal age group.^[6] Our patient had all the classical features. Males present with varying degrees of ambiguous genitalia with lack of secondary sexual characteristics.^[7] Approximately 90% patients are hypertensive or hypokalemic at presentation.

In humans 17- α -hydroxylase has two functions: (i) it hydroxylates pregnenolone and progesterone in the 17 position; and (ii) cleaves the steroid side-chains from 17-hydroxypregnenolone (17, 20 lyase activity) to convert it to the C-19 androgen precursor, DHEA.^[8] Deficiencies in CYP17 result in decreased synthesis of cortisol, C-19 androgens (dihydroepiandrosterone and androstenedione)

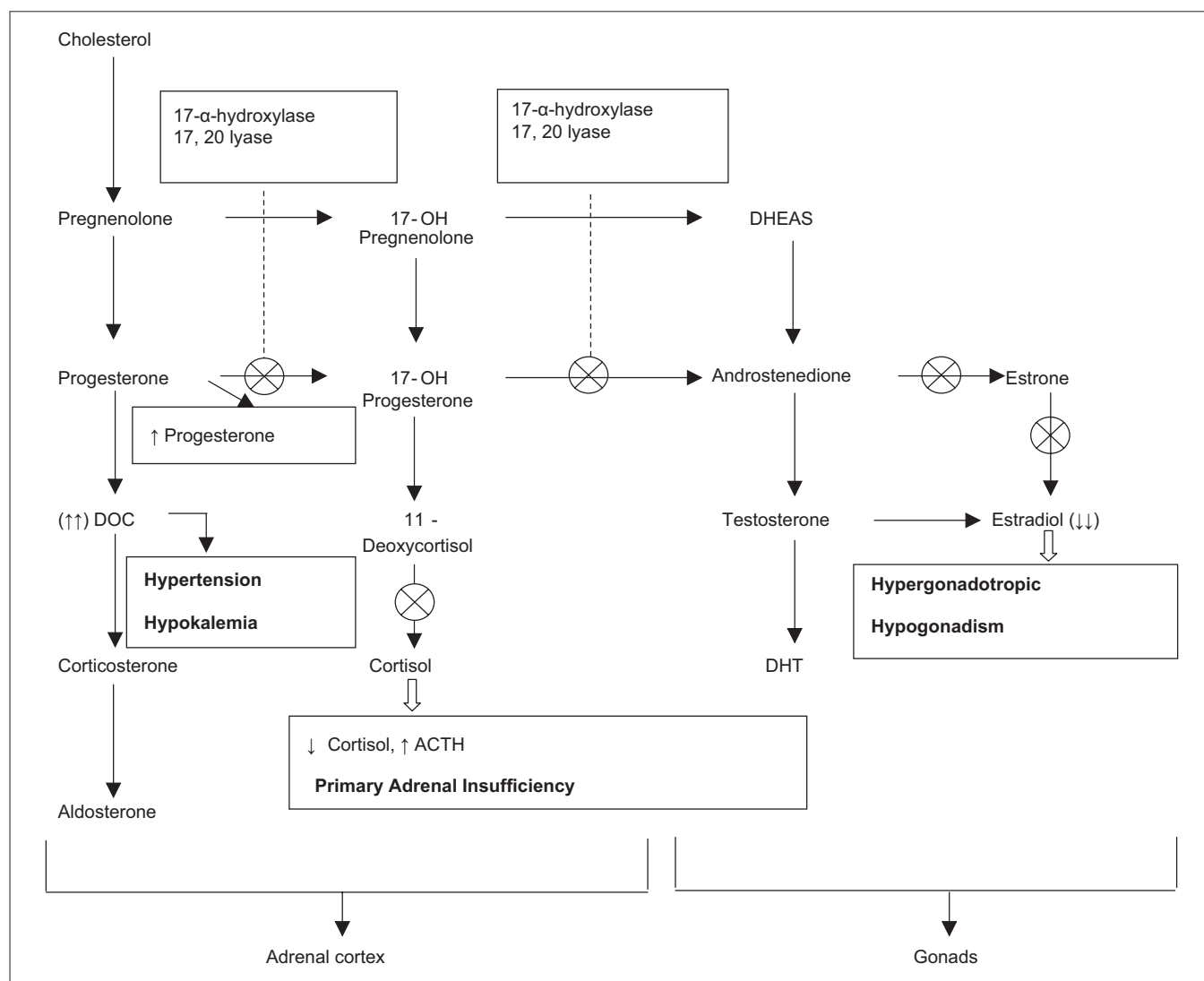


Figure 1: Steroidogenic pathway defects at various levels in 17OHD and relevant hormonal and clinical manifestations

and sex hormones. Adrenal insufficiency (due to decreased cortisol synthesis) does not manifest as classical Addison's disease because of increased production of corticosterone, a weaker glucocorticoid. Our patient also did not manifest with all the features of Addison's disease except having increased skin fold and knuckle pigmentation. This results in an increase in ACTH secretion, which in turn leads to increased synthesis of steroid intermediates, such as progesterone, 17- α -deoxysteroids (deoxycorticosterone [DOC] and corticosterone).^[9] DOC has a potent mineralocorticoid action and causes retention of sodium and water, hypokalemia, alkalosis, and hypertension. In consequence, the renin-angiotensin system is usually suppressed, resulting in decreased aldosterone synthesis leading to a state of hyporeninemic hypoaldosteronism.^[3] The low 24 h urine potassium at the baseline in our patient could be attributed to hypoaldosteronism. DOC levels are high in patients with 17- α -OHD, but could not be checked in our patient. High progesterone, the immediate proximal hormone alone could explain the block at 17- α -hydroxylase step [Figure 1].

Hypertension and hypokalemia responded to glucocorticoid treatment. Glucocorticoids suppress the high ACTH-induced mineralocorticoid excess.^[10] Mineralocorticoid antagonist, such as spironolactone and calcium channel blockers can be added to the regimen for better control of BP.^[11,12] Quadriparesis resolved with correction of hypokalemia, so no imaging was done.

Although the approach to a case with hypertension and hypokalemia requires initial measurements of plasma renin and aldosterone, in view of the current scenario with associated findings of hypergonadotropic hypogonadism, low cortisol with high ACTH, elevated progesterone, testing of renin and aldosterone was postponed. However, to complete the workup, plasma renin and aldosterone levels were checked 2 months later (after stopping prednisolone for 4 days, intended toward tapering the effect of glucocorticoid on renin-angiotensin axis). In our patient, findings of low renin and normal aldosterone could be related to gradual reversal of DOC-induced suppression of renin angiotensin axis by glucocorticoid therapy for 8 weeks.

Our patient had primary amenorrhea without any pubertal features and ambiguous genitalia with 46XX karyotype. Deficient estrogen production (exemplified by absent breast development) explains hypergonadotropic hypogonadism.

Absence of adrenal androgens explains absent pubic and axillary hairs in our patient. Estrogen therapy is given for induction of puberty and could be required with progesterone in later life to prevent osteoporosis.

CONCLUSION

17- α -Hydroxylase deficiency is a rare cause of CAH; however, it should be considered when 46XY sex reversal or 46XX pubertal failure occurs in association with hypokalemic hypertension, so that appropriate therapy can be implemented. A failure to do so will result in uncontrolled arterial hypertension and its sequelae.

REFERENCES

1. Chung BC, Picado-Leonard J, Haniu M, Hall PF, Shively JE, Miller WL. Cytochrome P457c17 cloning of human adrenal and testis cDNAs indicates the same gene is expressed in both tissues. *Proc Natl Acad Sci U S A* 1987;84:407-11.
2. New MI. Male Pseudohermaphroditism due to 17- α -Hydroxylase deficiency in man. *J Clin Invest* 1966;45:1946-54.
3. Grumbach MM, Hughes IA, Conte FA. Disorder of sex differentiation. In: Larsen PR, Kronenberg HM, Melmed S, editors. *Williams Textbook of Endocrinology*. 10th ed. Philadelphia: Saunders; 2003. p. 842-1002.
4. Biglieri EG. 17 α Hydroxylase deficiency. *J Clin Endocrinol Metab* 1997;82:42-50.
5. Neinstein LS, Kaufman FR. Normal Physical growth and development from Neinstein LS. *Adolescent health care: A practical guide*. 4th ed. Chapter 1. Hagerstown, MD: Lippincott Williams and Wilkins; 2002.
6. Biglieri EG, Herron MA, Brust N. 17- α -Hydroxylase deficiency in man. *J Clin Invest* 1966;45:1946-54.
7. Yanase T, Simpson ER, Waterman MR. 17- α -Hydroxylase/ 17, 20 Lyase deficiency: From clinical investigation to molecular definition. *Endocr Rev* 1991;12:91-108.
8. Lin D, Hari Krishna JA, More CC, Jones KL, Miller WL. Missense mutation series 106-proline causes 17 α Hydroxylase deficiency. *J Biol Chem* 1991;266:15992-8.
9. New MI. Male Pseudohermaphroditism due to 17 α Hydroxylase deficiency in man. *J Clin Invest* 1966;45:1946-54.
10. Peter M, Sippell WG, Wernze H. Diagnosis and treatment of 17 α Hydroxylase deficiency. *J Steroid Biochem Mol Biol* 1993;45:107-16.
11. Mantero F, Opocher G, Rocco S, Carpenè G, Armanini D. Long term treatment of mineralocorticoid excess syndrome. *Steroids* 1995;60:81-6.
12. Kater CE, Biglieri EG. Disorders of steroid 17 α Hydroxylase deficiency. *Endocrinol Metab North Am* 1994;23:341-57.

Cite this article as: Kota SK, Modi K, Jha R, Mandal SN. 17- α -Hydroxylase deficiency: An unusual case with primary amenorrhea and hypertension. *Indian J Endocr Metab* 2011;15:127-9.

Source of Support: Nil, **Conflict of Interest:** None declared.